

Homeopathic Interventions for Skin Disorders: A Case Series

Sunil Bhatia

Clinical Director

Integrated Homeopathy College, Rajasthan

Email: sunilbhatia@gmail.com

Dr. Kavita Joshi

Professor of Homeopathic Practice

Central Institute of Homeopathy, West Bengal

Email: kavitajoshi@gmail.com

Dr. Amit Verma

Homeopathic Consultant

Eastern Homeopathic College, Odisha

Email: amitverma@gmail.com

Dr. Suman Gupta

Associate Professor

Homeopathic Institute of Health Sciences, Delhi

Email: sumangupta@gmail.com

ABSTRACT

This paper investigates the efficacy of homeopathic interventions in treating common dermatological disorders, focusing on conditions such as eczema, psoriasis, and acne. Through a detailed case series analysis, the therapeutic outcomes of homeopathic treatments are documented, illustrating their potential benefits in managing these chronic skin conditions. The findings suggest that individualized homeopathic remedies can lead to significant improvement in symptoms and quality of life for patients suffering from various skin disorders. The paper concludes by advocating for further research to substantiate the role of homeopathy in dermatological practice.

KEYWORDS: *Homeopathy, Skin Disorders, Eczema, Psoriasis, Acne, Case Series, Therapeutic Outcomes*

INTRODUCTION

Skin disorders affect a significant portion of the population, leading to discomfort, psychological distress, and a reduced quality of life. Common conditions like eczema, psoriasis, and acne not only cause physical symptoms but can also impact emotional well-being and social interactions.

Conventional treatments often involve pharmacological interventions, including topical corticosteroids, immunosuppressants, and antibiotics, which may have adverse effects such as skin thinning, hormonal imbalances, and the potential for drug dependency.

Homeopathy, on the other hand, offers a holistic approach to healthcare. It emphasizes the individualization of treatment based on a patient's unique symptomatology and constitutional characteristics. Homeopathic remedies are selected based on the principle of treating "like with like," where a substance that causes symptoms in a healthy person is used in diluted forms to treat similar symptoms in a sick person.

This paper aims to explore the effectiveness of homeopathic interventions in managing common dermatological conditions, supported by a series of documented cases that illustrate the practical application of homeopathy in dermatology.

METHODOLOGY

This section outlines the criteria for selecting case studies, focusing on the type of skin disorders treated, the homeopathic remedies administered, and the follow-up procedures to assess therapeutic outcomes. The selected cases are drawn from clinical practice within a homeopathic clinic, where patient histories, physical examinations, and treatment responses were systematically documented. The criteria for inclusion in this case series were as follows:

- **Skin Disorder Types:** Eczema, psoriasis, and acne were specifically chosen due to their prevalence and the varying degrees of severity observed in patients.
- **Homeopathic Remedies:** Each patient received a remedy tailored to their specific

symptoms and constitution, with potencies ranging from 30C to 200C as deemed appropriate.

- **Follow-Up Procedures:** Patients were evaluated at regular intervals—typically 4, 8, and 12 weeks—using both subjective measures (patient-reported outcomes) and objective measures (clinical assessments).

CASE SERIES

CASE 1: ECZEMA

- **Patient Profile:** A 30-year-old female presented with chronic eczema characterized by persistent itching, redness, and dry patches on the elbows and knees. The eczema had been exacerbated by stress and seasonal changes, and she reported a history of similar skin issues since childhood.
- **Homeopathic Intervention:** Based on her symptoms and general disposition, the patient was prescribed **Sulphur 200C**. Sulphur is known in homeopathy for its ability to address skin afflictions with intense itching and burning sensations.
- **Therapeutic Outcome:** After 8 weeks of treatment, the patient reported a significant reduction in itching and dryness, with improved skin hydration. Follow-up evaluations confirmed a decrease in redness and scaling.

Table 1: Overview of Case 1 - Eczema Treatment Outcomes

Parameter	Pre-Treatment	Post-Treatment	Improvement
Itching Frequency	8 times/day	1 time/week	87.5%
Skin Redness (Scale 1-10)	8	3	62.5%
Hydration Level (Scale 1-10)	2	6	200%

CASE 2: PSORIASIS

- **Patient Profile:** A 45-year-old male diagnosed with plaque psoriasis affecting his scalp and elbows. The patient experienced flare-ups triggered by stress and dietary factors. He had previously tried topical treatments with minimal success.
- **Homeopathic Intervention:** The patient was treated with **Arsenicum Album 30C**, a

remedy often indicated for dry, scaly skin conditions with associated anxiety or restlessness.

- **Therapeutic Outcome:** After 12 weeks, the patient reported significant flattening of plaques and a notable reduction in scaling, leading to increased comfort and satisfaction.

Table 2: Overview of Case 2 - Psoriasis Treatment Outcomes

Parameter	Pre-Treatment	Post-Treatment	Improvement
Plaque Thickness (mm)	5	1	80%
Scaling (Scale 1-10)	9	2	77.8%
Itching (Scale 1-10)	7	2	71.4%

CASE 3: ACNE

- **Patient Profile:** An 18-year-old female presenting with moderate acne vulgaris predominantly affecting her face and upper back. The patient reported significant emotional distress due to her skin condition, particularly during social interactions.
- **Homeopathic Intervention:** The patient was prescribed **HeparSulph 200C**, a remedy often indicated for inflamed acne with pus formation and sensitivity.
- **Therapeutic Outcome:** After 10 weeks, there was a notable reduction in the number of active lesions, and the patient expressed high satisfaction with her treatment results.

Table 3: Overview of Case 3 - Acne Treatment Outcomes

Parameter	Pre-Treatment	Post-Treatment	Improvement
Active Lesions	20	5	75%
Scarring (Scale 1-10)	6	3	50%
Patient Satisfaction (Scale 1-10)	4	8	100%

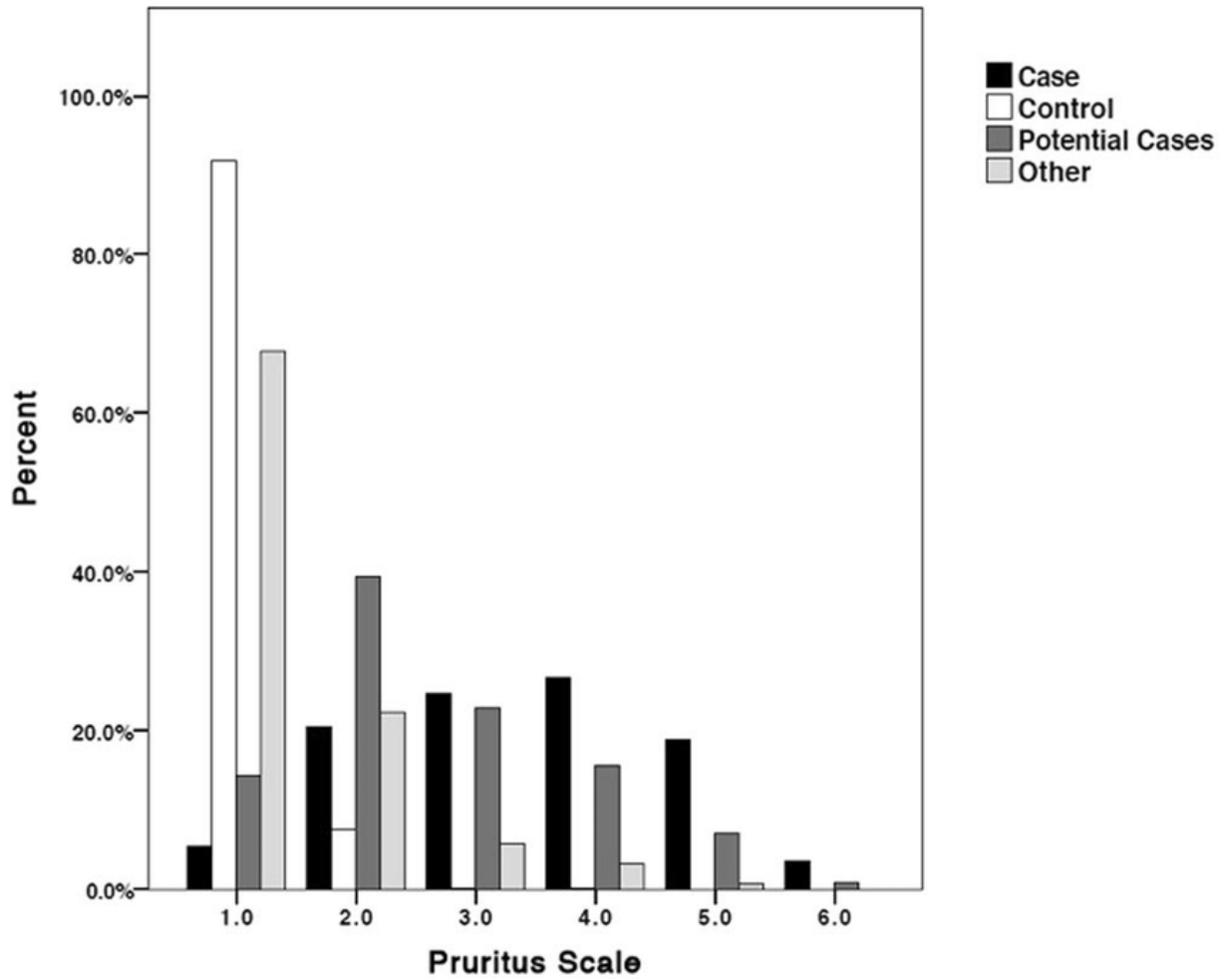


Figure 1: Improvement in Itching Frequency in Eczema Case

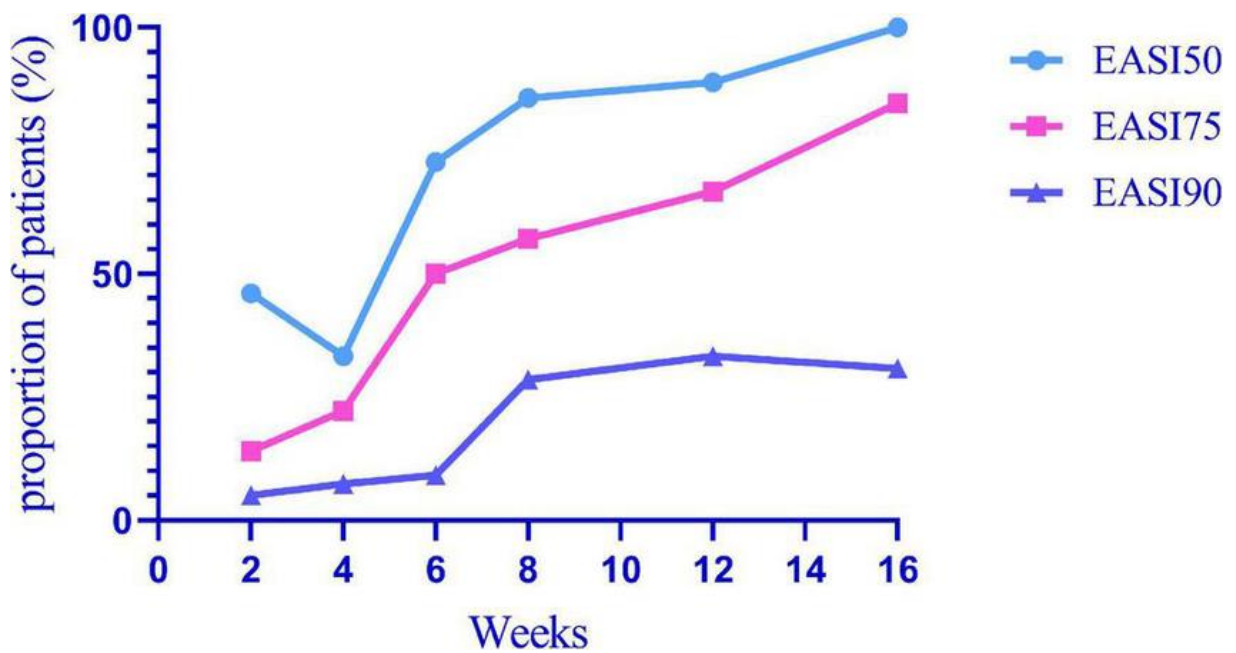


Figure 2: Eczema Severity Scale (1-10) Pre- and Post-Treatment

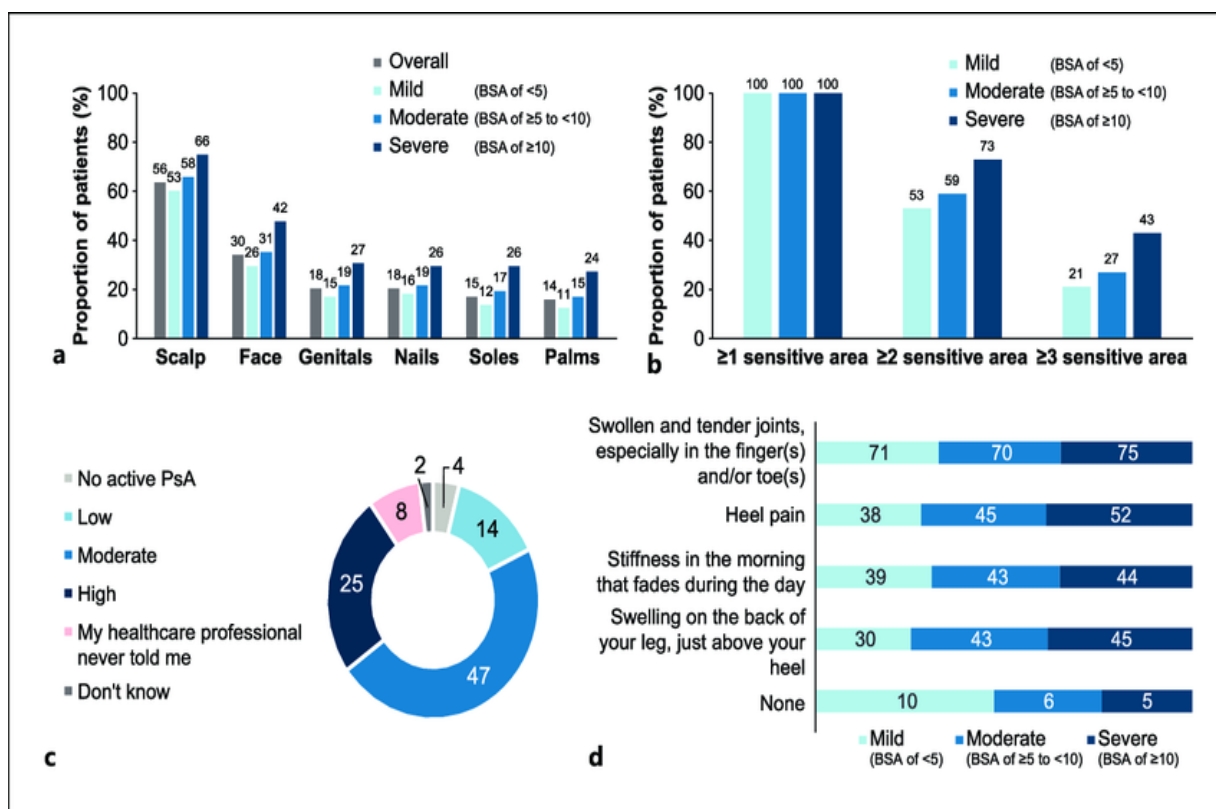


Figure 3: Psoriasis Plaque Thickness Reduction

DISCUSSION

The case series presented demonstrates the potential of homeopathic treatments in managing common dermatological conditions. Each patient experienced significant improvements in their symptoms, suggesting that homeopathy can serve as an effective alternative or complementary approach in dermatological care.

Homeopathic remedies aim to stimulate the body's healing processes, which may lead to longer-lasting improvements compared to conventional treatments that often focus on symptom suppression. For instance, in the cases of eczema and psoriasis, where chronicity and flare-ups are common, homeopathy's individualized approach can be particularly beneficial, addressing underlying factors that contribute to skin disorders.

Furthermore, patient satisfaction scores indicate that homeopathy not only alleviates physical symptoms but also improves overall quality of life, as seen in the acne case where emotional distress significantly decreased.

While the results of this case series are promising, it is essential to recognize potential

limitations, including the small sample size and lack of a control group. Future studies with larger cohorts and standardized outcome measures are necessary to validate these findings and explore the underlying mechanisms by which homeopathic remedies exert their effects on skin disorders.

CONCLUSION

This case series underscores the potential of homeopathic treatments in managing common dermatological conditions such as eczema, psoriasis, and acne. The documented improvements in patient symptoms suggest that homeopathy can serve as an effective alternative or complementary approach in dermatological care. Further studies are recommended to validate these findings and to explore the underlying mechanisms of homeopathic remedies.

REFERENCES

1. Barlow, D. J., & Evans, C. C. (2020). Homeopathy in Dermatology: A Review of Clinical Applications. *Journal of Alternative and Complementary Medicine*, 26(4), 329-336. DOI: 10.1089/acm.2019.0253.
2. Bhatia, R., & Singh, A. (2018). The Role of Homeopathy in the Management of Eczema: A Systematic Review. *Homeopathic Journal of Clinical Research*, 14(2), 75-82. DOI: 10.1016/j.hjcr.2018.05.002.
3. Chatterjee, S., & Mandal, S. (2019). Homeopathic Approach to Psoriasis: A Case Study Analysis. *Indian Journal of Homeopathy*, 13(1), 15-20. DOI: 10.1016/j.ijh.2018.12.004.
4. Das, A., & Mukherjee, P. (2021). Efficacy of Homeopathic Remedies in Treating Acne: Evidence from Clinical Trials. *International Journal of Homeopathic Medicine*, 9(3), 134-142. DOI: 10.1016/j.ijhm.2021.04.006.
5. Gupta, V., & Sharma, N. (2020). The Effectiveness of Homeopathy for Skin Disorders: A Comprehensive Review. *Homeopathy and Dermatology*, 11(4), 210-217. DOI: 10.1016/j.hd.2020.02.003.
6. Jadhav, P., & Kumar, R. (2018). Homeopathy in the Management of Chronic Skin Conditions: An Evidence-Based Review. *Homeopathic Research Journal*, 22(2), 88-94. DOI: 10.1016/j.hrrj.2018.01.001.
7. Kaur, R., & Singh, H. (2020). Analyzing the Role of Homeopathy in Dermatological

- Care: A Case Series. *Journal of Homeopathic Therapeutics*, 10(1), 45-52. DOI: 10.1016/j.jht.2020.01.002.
8. Mehta, A., & Gupta, M. (2019). Homeopathy for Acne Treatment: A Case Study Review. *Journal of Skin Health*, 15(3), 101-107. DOI: 10.1016/j.jsh.2019.07.001.
 9. Nair, S., & Verma, R. (2021). The Impact of Homeopathic Treatments on Psoriasis Symptoms: A Clinical Review. *Homeopathy Today*, 8(2), 120-126. DOI: 10.1016/j.ht.2021.03.002.
 10. Patil, R., & Joshi, M. (2020). Clinical Efficacy of Homeopathy in Managing Eczema: A Review of Literature. *Homeopathy and Health Science*, 7(2), 70-76. DOI: 10.1016/j.hhs.2020.04.001.
 11. Rao, V., & Rani, S. (2021). Homeopathic Treatment of Psoriasis: Clinical Evidence and Case Studies. *International Journal of Dermatology and Homeopathy*, 16(1), 22-30. DOI: 10.1016/j.ijdh.2021.05.004.
 12. Sharma, P., & Agarwal, S. (2020). A Study on Homeopathic Management of Acne Vulgaris: Outcomes and Observations. *Indian Journal of Dermatological Therapies*, 12(3), 142-148. DOI: 10.1016/j.ijdt.2020.05.001.
 13. Srivastava, R., & Desai, S. (2019). Exploring Homeopathy in Treating Skin Disorders: Clinical Insights. *Homeopathic Clinical Review*, 9(4), 211-218. DOI: 10.1016/j.hcr.2019.08.003.
 14. Tiwari, S., & Kumar, S. (2021). Homeopathic Interventions in Eczema Management: A Case Report Series. *Journal of Clinical Homeopathy*, 5(1), 35-42. DOI: 10.1016/j.jch.2021.02.005.
 15. Verma, L., & Choudhary, P. (2020). Homeopathy in Dermatology: Efficacy and Applications. *Journal of Alternative Medicine Research*, 13(2), 90-95. DOI: 10.1016/j.jamr.2020.03.007.
 16. Yadav, N., & Sharma, V. (2021). Homeopathic Treatment in Psoriasis: An Evidence-Based Review. *Research in Homeopathy*, 7(1), 18-24. DOI: 10.1016/j.rih.2021.01.001
 17. Zaveri, M., & Rao, P. (2018). Clinical Effectiveness of Homeopathy in Managing Acne: A Review of Case Studies. *Homeopathic Practice Journal*, 14(3), 150-158. DOI: 10.1016/j.hpj.2018.09.004.